
Ameliorative Effects of Erdosteine and Exogenous Reduced Nicotinamide Adenine Dinucleotide Phosphate on Aluminium Phosphide Induced Cardiotoxicity in Adult Albino Rats.

Wafaa S. A. Elbadawy¹, Eslam S. Metwally¹, Nagah E.M. Ali¹ and Maha M. Mokhtar¹

¹Department of Forensic Medicine & Toxicology, Faculty of Medicine, Benha University, Benha 13518, QG, Egypt.

ABSTRACT

The present study was performed to determine the possible protective effects of erdosteine and exogenous reduced nicotinamide adenine dinucleotide phosphate (NADPH) against cardiotoxicity produced by aluminium phosphide (AIP) via measurement of serum cardiac markers and assessment of cardiomyocyte viability and apoptosis by flow cytometry analysis. Fifty- four adult albino rats were divided into seven groups as follows; four control groups (negative control, solvent control, erdosteine control, NADPH control), AIP group (12 mg/kg) orally, AIP + erdosteine (150 mg/kg) orally, AIP + NADPH (16 mg/kg) intravenously. After 8 hours, blood samples were collected from the retro-orbital plexus for analysis of serum cardiac markers, and then the chest and abdomen were carefully incised to remove the hearts for flow cytometry analysis and histopathological examination. Results revealed that AIP poisoning caused an increase in serum cardiac markers (LDH, cTnI) with a marked decrease in the viability of cardiac myocytes and a marked increase in the percent of apoptotic cardiac myocytes. Co-administration of erdosteine with AIP slightly improved serum cardiac markers and cardiomyocyte viability with a slight decrease in the percent of apoptosis. Co-administration of NADPH with AIP showed marked improvement in serum cardiac markers, a marked increase in myocardial cell viability, and a marked decrease in the percent of apoptotic myocytes. These findings were confirmed by histopathological examination of heart tissues from each group. From the previous data, it can be concluded that administration of exogenous NADPH intravenously may be a promising antidote for AIP toxicity.

Keywords: *Aluminium phosphide, Erdosteine, NADPH, Cardiotoxicity, Rats.*

INTRODUCTION

Aluminium phosphide (AIP) is a solid fumigant insecticide used to protect food products during storage. In Egypt, the use of aluminium phosphide for suicide has been increasing over the last few years. Salah Eldin and Azim (2018) stated that the number of deliberate self-poisoning by phosphides has increased from 2015 to 2016 in the Poison Control Center of Ain Shams University Hospitals. Another study in Menoufia city demonstrated that AIP poisoning formed 18.75% of metal phosphides intoxicated patients (Badawi et al., 2018). This percentage just represents a small part of the problem since most cases of poisoning pass unreported (El Naggar and El Mahdy, 2011).

The tablet of AIP is known as the wheat pill or rice tablet. It is marketed under many trade names, such as Celphos, Quickphos, and Phostoxin, especially in developing countries. Its availability, cheapness, and high efficacy have made AIP one of the leading methods of suicide recently (Eshraghi et al., 2019).

A high mortality rate is recorded in AIP intoxicated patients, usually due to multi-organ failure, even when they are in the intensive care unit, as there is no available antidote till now (Farzaneh et al., 2018).

The heart is the most affected organ in AIP poisoning, and most deaths occur within the first 12–24 hours after exposure due to cardiovascular complications (Beyranvand et al., 2019).

Phosphine is considered a protoplasmic poison; it acts by several mechanisms inside the cell, but its actual mechanism of toxicity is still unknown. Phosphine has a nucleophilic nature; it acts as a strong reducing agent, forming coordinate bonds with metals. Therefore, it damages critical biomolecules, disrupting their function, such as the cytochrome C oxidase enzyme and catalase enzyme (Lyubimov and Garry, 2010).

Phosphine partially blocks the cytochrome C oxidase enzyme, complex IV in the electron transport chain, thus causing inhibition of the mitochondrial oxidative phosphorylation by 70% and generation of uncontrolled amounts of oxygen free radicals that induce oxidative stress and mitochondrial dysfunction (Ghazi, 2013). Mitochondrial dysfunction triggers the release of mitochondrial intermembrane space agents into the cytosol, such as cytochrome C. These agents are involved in the initiation of the apoptosis pathway of the cell (Aminjan et al., 2019).

Cardiac muscle is very rich in mitochondria due to its high oxygen and energy demand. So, inhibition of oxidative phosphorylation and triggering of apoptosis may be the primary causes of cardiac dysfunction in AIP toxicity (Sciuto et al., 2016).

Cardiac troponin I (cTnI) is a specific biomarker for cardiac injury (Bameri et al., 2021). Lactate dehydrogenase enzyme (LDH) is a cytoplasmic enzyme that presents in high concentrations in muscles, it raises in anaerobic conditions (Farhana and Lappin, 2021). So, both markers are used as indicators for cardiac injury.

Erdosteine is used as a mucolytic drug. It has two blocked thiol groups responsible for its antioxidant activity, so it has been widely used recently in experimental research (Birdane et al., 2021).

Reduced nicotinamide adenine dinucleotide phosphate (NADPH) is the main reducing power in the cell. It forms two separate reducing pools in the cytosol and mitochondria (Lewis et al., 2014).

The principal biological function of NADPH is to provide redox capacity for the antioxidant systems such as the glutathione system, thioredoxin system, and catalase enzyme (Xiao et al., 2018).

Moreover, NADPH is the main hydrogen and electron donor in reductive biosynthesis reactions involved in lipid and protein synthesis. Also, it participates indirectly in DNA synthesis (Agleedal et al., 2010). Recent studies proved that exogenous NADPH could be beneficial in treating acute pathological conditions, such as myocardial injury (Zhu et al., 2019).

The present study aimed to determine the possible ameliorative effects of erdosteine and exogenous NADPH against cardiac toxicity produced by aluminium phosphide.

Materials and methods

Chemicals:

Aluminium phosphide was purchased from a local pesticide shop in Benha city, in the form of 3 gm tablets (56% concentration, Excel Crop Care Ltd., India). Erdosteine capsules were purchased from the local market (Mucotec, 300mg, Global Nabi Pharmaceuticals Company, 6th of October, Egypt). NADPH Tetrasodium salt white powder, with a purity of 97%, was purchased from the local agency of Sigma Chemical Company.

Animals:

Fifty-four adult albino rats (200–250 g) were used. All ethical considerations for animal treatment were followed according to the Ethics Committee of Scientific Research, Faculty of Medicine, Benha University (code: MS-9-4-2020). The current experiment was done in the summer (July 2021) in the animal bread house of the faculty of veterinary medicine, Benha University.

Route of administration:

Both AIP and erdosteine were given orally using a metallic cannula of appropriate size. NADPH was given by intravenous injection in the tail vein, using a suitable rat restrainer, by an insulin syringe (1 ml) with a suitable gauge.

Experimental design:

At the beginning of the experiment, rats were randomly divided into nine groups, six rats for each group, as follows:

Group I (negative control group): rats were left without intervention to measure the basic parameters while having free access to food and distilled water.

Group II (solvent control groups); **Group IIa** (normal saline control group) received a single oral dose of normal saline by gavage tube. **Group IIb** (modified saline control group) was treated with a single intravenous dose of (1 ml of modified saline solution) with PH:8 (normal saline +10% NaOH) (Zhu et al., 2019). **Group IIc** (corn oil control group) received a single oral dose of (1 cc of corn oil) by gavage tube (Ahmadi et al., 2018).

Group III (erdosteine-treated control group) received a single dose of erdosteine 150 mg/kg dissolved in normal saline 0.9% orally by gavage tube (Demiralay et al., 2006). **Group IV** (NADPH treated control group): received a single intravenous dose of NADPH 16 mg/kg dissolved in 1ml of modified saline with pH: 8 (normal saline +10% NaOH) (Zhu et al., 2019). **Group V** (AIP treated group) received a single dose of AIP 12 mg/kg orally by gavage tube. The tablets were freshly powdered and suspended in corn oil. **Group VI** (AIP + erdosteine treated group) received a single dose of AIP 12 mg/kg orally by gavage tube, followed by a single dose of erdosteine 150 mg/kg orally, 1h after the AIP dose. **Group VII** (AIP + NADPH treated group) received a single dose of AIP 12 mg/kg orally by gavage tube, followed by a single dose of NADPH 16 mg/kg, dissolved in 1 ml of modified saline with pH: 8, IV, 1 hour after AIP administration. All studied groups were exposed to fasting after AIP ingestion.

After 8 hours, mortality started to appear in the AIP group, and live rats in the same group were in a morbid state. So, live rats from the AIP group and rats from all other groups were anaesthetized with ether inhalation for taking samples.

Collection of samples:

Blood samples were collected by puncture of the retro-orbital plexus. Hearts were removed by opening abdominal and chest cavities then cleaned and divided into two parts; one part was placed in 10% formalin for histopathological examination, and the second part was used freshly for flow cytometry analysis and was transported to the lab in isotonic saline. Blood and flow cytometry samples were analyzed in the central lab of the Faculty of Veterinary Medicine, Benha University.

Biochemical analysis of serum cardiac markers:

Collected blood samples were centrifuged at 3000 rpm for 10 min at 4°C. The clear non-hemolyzed supernatant serum was used for the estimation of LDH and cTnI.

Lactate dehydrogenase (LDH) level was measured spectrophotometrically using the commercial test of LDH (Genesis Lab for Diagnostic Reagents), Egypt.

Cardiac troponin I (cTnI) levels were determined using a fluorescence immunochromatographic analyzing system using the commercial test of troponin I (Guangzhou Wondfo Biotech Co., Ltd), China.

Flow cytometry analysis:

This analysis aimed to evaluate cardiomyocyte death using annexin-V Fluorescein isothiocyanate (FITC) and propidium iodide (PI), which stains phosphatidylserine and DNA residues (Vermes et al., 1995).

Fresh heart specimens were prepared according to Tribukait et al. (1975), stained according to the protocol of the annexin V kit (cat. No.556547 BD pharmingen FITC apoptosis Kit), then analyzed by flow cytometry (BD accuri c6, Becton, Dickinson and Company, USA) using (Accuri c6 software).

Histopathological examination of the heart:

Histopathological examination of collected heart samples was done at the Pathology Department, Faculty of Medicine, Benha University, using Haematoxylin and Eosin (H&E) and examined by a light microscope (OLYMPUS, Japan).

Statistical analysis

The data were analyzed using the SPSS program, (Spss Inc, Chicago, ILL Company) version 26. Descriptive statistics were calculated in the form of mean and standard deviation (SD) for quantitative data. The significance of the difference between the studied groups was tested using one of the following tests: the ANOVA test (analysis of variance), to compare the mean of more than two groups, the Post hoc test (Least significant difference, LSD) for intergroup comparisons.

Results

Observations during the study:

Some behavioral changes have been observed in the AIP treated group in the form of a decrease in rats' movement. These changes were less pronounced in the groups treated with (AIP+ erdosteine) and (AIP+ NADPH). Mortality was recorded in the AIP treated group, while no mortality was observed in the (AIP+ erdosteine) and (AIP+ NADPH) treated groups.

As regards the control groups (negative control), (solvent control), (erdosteine control), and (NADPH control), they showed non-significant differences ($p > 0.05$) as regards serum levels of cardiac troponin I (cTnI), lactate dehydrogenase enzyme (LDH) and flow cytometry parameters. So, the mean of all control groups was chosen as a representative group for the four control groups to be compared with the results of the remaining groups.

Biochemical cardiac markers:

A highly significant ($p < 0.001$) increase in LDH level was found in the (AIP group) when compared with the control group. The group of (AIP + erdosteine) showed a reduction in LDH level, and the (ALP + NADPH) group showed a marked decrease in LDH level when compared with the (AIP treated group). No significant difference was found between groups VI and VII, as shown in table (1).

A highly significant ($p < 0.001$) increase in cTnI level was found in the (AIP group) when compared with the control group. Co-administration of (AIP + erdosteine) caused a reduction in cTnI level, while co-administration of (ALP+ NADPH) showed a marked decrease in cTnI level when compared with the (AIP group). No significant

difference was found between; (the control group & group VI); (the control group & group VII); and (group VI & group VII) (Table 2).

Table (1): Comparison between studied groups regarding serum LDH level (U/L).

LDH	Mean	± SD	Range	ANOVA	p-value
Control group	432.81	35.94	349-499		
Group V (ALP)	4169.0 ^a	267.363	3876- 4540	356.3	<0.001**
Group VI (ALP + erdosteine)	1701.00 ^{ab}	471.107	990- 2152		
Group VII (ALP+ NADPH)	1452.33 ^{abd}	561.893	875- 2280		

** : highly significant. **a** highly significant difference when compared with the control group at $p < 0.001$. **b** highly significant difference when compared with the AIP group (V) at $p < 0.001$. **d** indicates a non-significant difference when compared with group VI (AIP+ erdosteine), $p > 0.05$.

Table (2): Comparison between the studied groups regarding serum cTnI level (ng/ml).

Troponin	Mean	± SD	Range	ANOVA	p-value
Control group	0.031	0.01	0.02-0.05		
Group V (ALP)	0.48 ^a	0.315	0.1-0.83	35.85	<0.001**
Group VI (ALP +erdosteine)	0.090 ^b	0.035	0.05-0.15		
Group VII (ALP+ NADPH)	0.048 ^{bd}	0.015	0.03-0.07		

** : highly significant. **a** highly significant difference when compared with the control group at $p < 0.001$. **b** highly significant difference when compared with AIP group (V) at $p < 0.001$. **d** indicates a non-significant difference when compared with group VI (AIP+ erdosteine), $p > 0.05$.

Flow cytometry analysis of cardiac myocytes:

As regards the parameters of flow cytometry analysis, there was a highly significant ($p < 0.001$ **) decrease in the live myocardial cell percent in the AIP treated group when compared with the control group (Figure 2a, 2b). The group of (AIP + erdosteine) showed a slight increase in the live myocardial cell percent as shown in figure (2c), while the group of (AIP + NADPH) showed a marked increase in the cell viability when compared with the AIP group (Figure 2d). As regards early apoptotic cell percent, it showed a highly significant decrease in all studied groups when compared with the control group. Late apoptotic cell percent showed a marked increase in the AIP group, (AIP + erdosteine) group showed a decrease in the late apoptotic cell percent, while (AIP + NADPH) group showed a marked decrease in the late apoptotic cell percent when compared with the AIP group, with a non-significant difference with the control group. The percent of necrotic cells was highly elevated in the AIP group and (AIP + erdosteine), then showed a marked decrease in (AIP + NADPH), but the mean value of this group was still higher than the control (Figure 1).

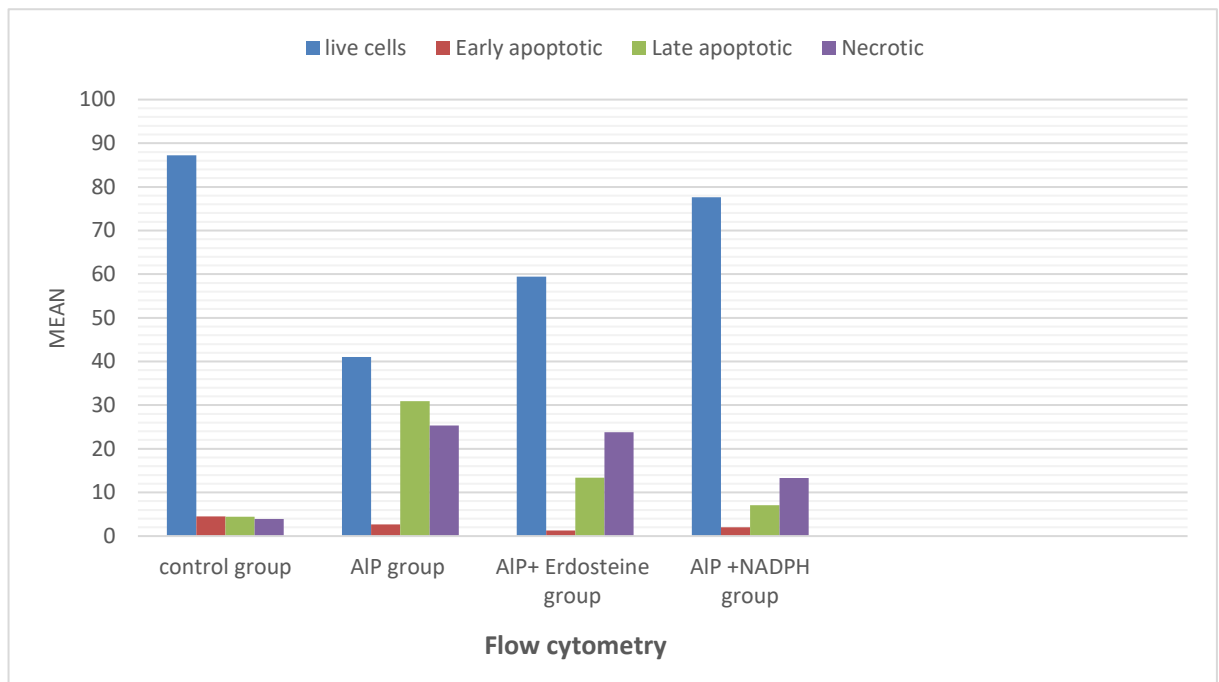


Fig. (1): Comparison between studied groups regarding flow cytometry analysis of cardiac myocytes.

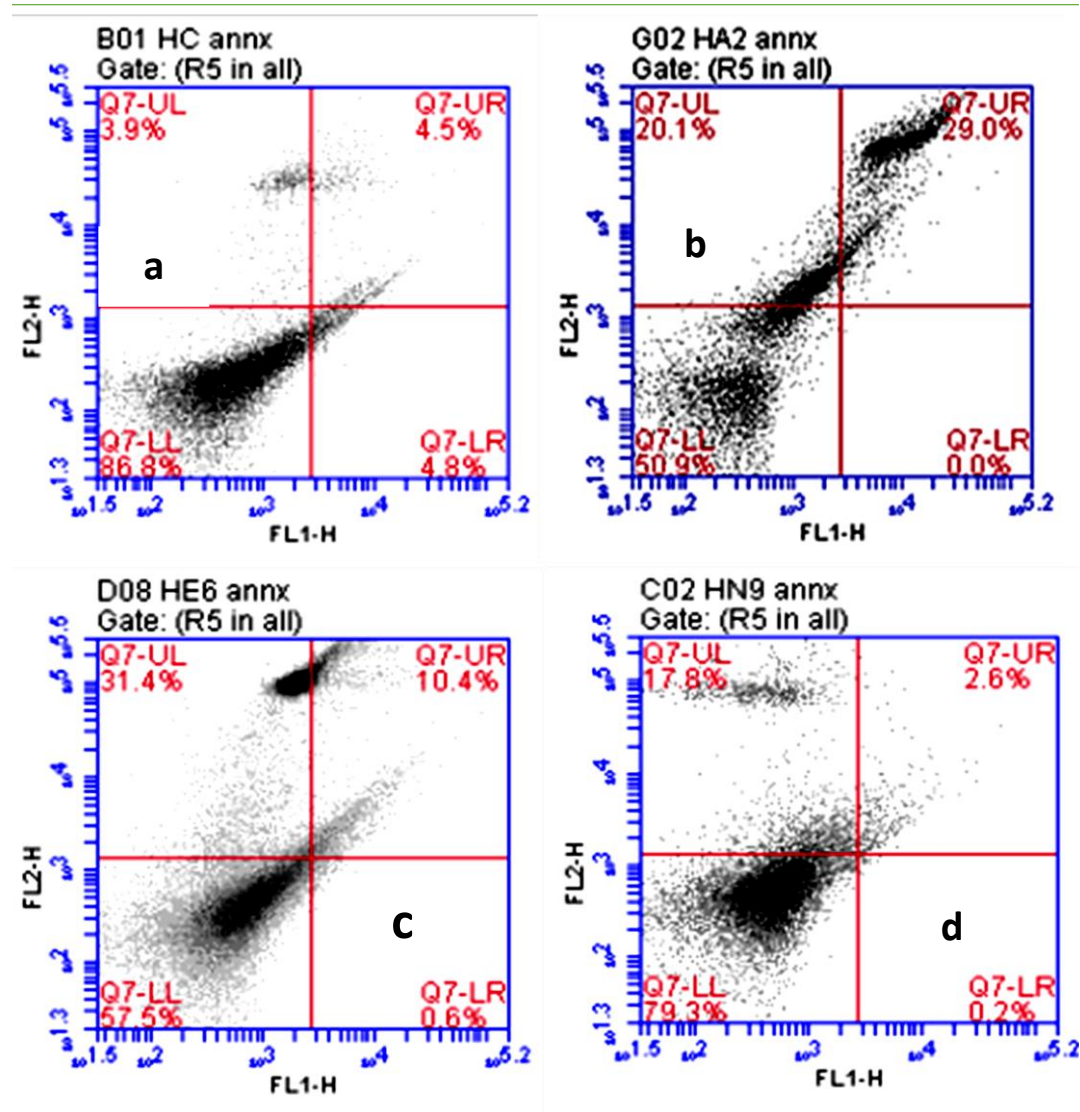


Fig. (2): Comparison between studied groups regarding flow cytometry analysis of cardiac myocytes, using Annexin-V/PI staining, regarding the viability and cell death. a: Live cells; 86.8% (annexin V⁻/PI⁻), are in the lower left quadrant (LL). Early apoptotic cells (annexin V⁺/PI⁻), are in the lower right quadrant (LR). Late apoptotic cells (annexin V⁺/PI⁺) are in the upper right quadrant (UR). Necrotic cells (annexin V⁻/PI⁺) are in the upper left quadrant (UL). b: AIP administration alone decreased the percentage of viable cardiomyocytes to 50.9% and increased the rate of late apoptotic and necrotic cardiomyocytes. c: co-administration of erdosteine with AIP slightly increased cardiomyocytes' viability to 57.5% and decreased the rate of late apoptotic cells. d: co-administration of NADPH with AIP caused a marked increase in cardiomyocyte viability to 79.3% and a decrease in the rate of early, late apoptotic, and necrotic cardiomyocytes, and this result was similar to the control group.

Histopathological Results:

In control groups (negative control, solvent control, erdosteine control, NADPH control), heart sections showed almost the same structures with non-significant histopathological changes in the form of parallel regularly arranged cylindrical branched striated muscle fibers, centrally placed oval vesicular nuclei, and flattened

nuclei of interstitial fibroblasts. The negative control group was representative of other control groups, as shown in figure (3a).

In the (AIP group), heart sections showed severe fibers disruption, disarranged cardiomyocytes with wide myocardium interstitium, and areas of myocardial cell degeneration and necrosis (Figure 3b).

In the (AIP+ erdosteine treated group), heart sections showed a fewer fiber disruption, less cardiomyocytes degeneration, and no necrosis when compared with the AIP group (Figure 3c).

In the (AIP + NADPH treated group), heart sections showed apparent normal cardiac architecture similar to that of the control group, in the form of parallel cylindrical branching muscle fibers and centrally placed nuclei (Figure 3d).

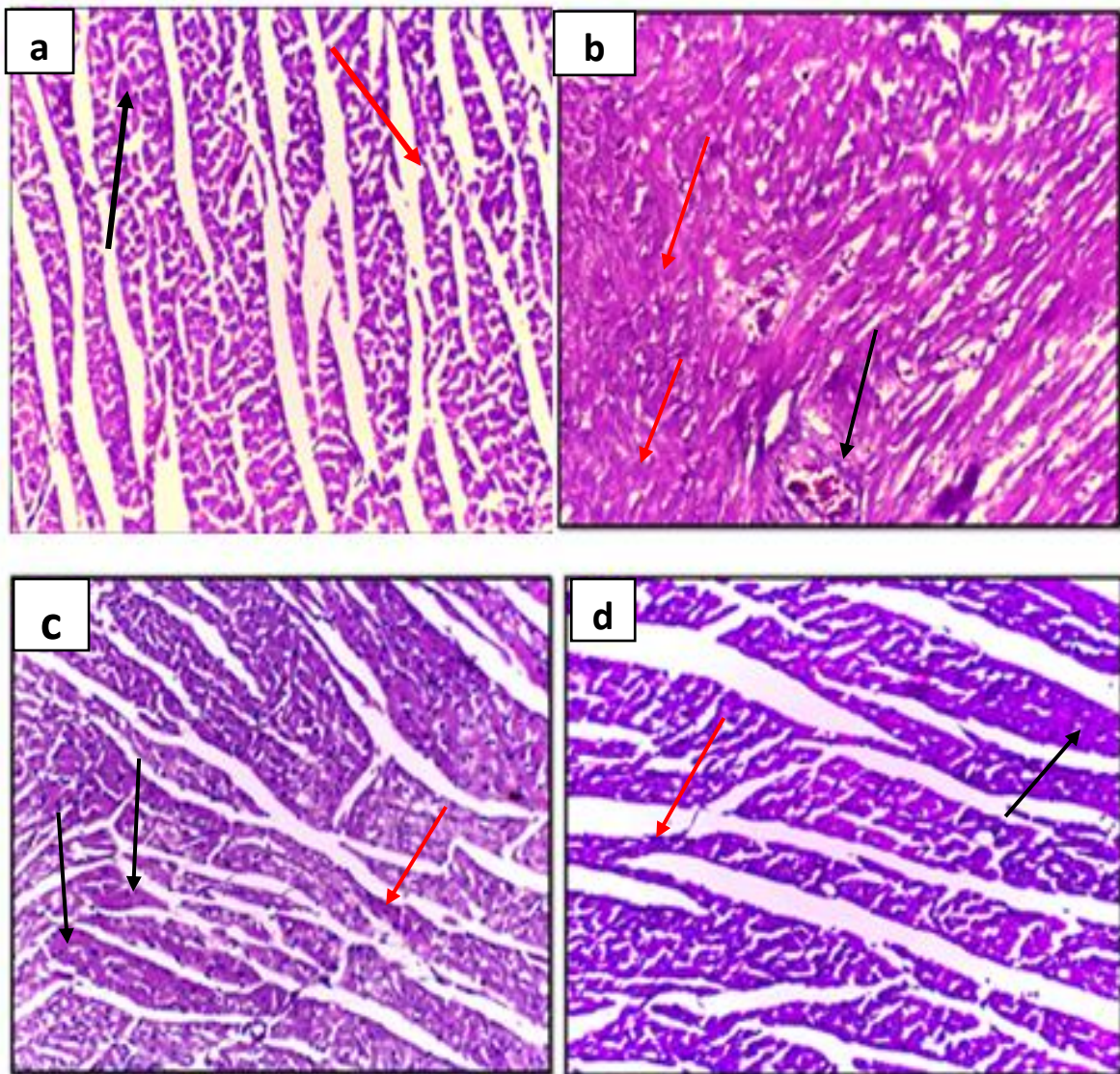


Fig. (3): Photomicrographs of a section of a rat's heart prepared from a: control group showed normal cardiac architecture in the form of parallel, regularly arranged

cylindrical branched striated muscle fibers (red arrow), centrally placed oval vesicular nuclei (black arrow), (H&E, x 200). b: The AIP treated group showed severe fiber disruption, areas of myocardial cell degeneration and necrosis (red arrow), and congested blood vessels with perivascular inflammatory cells (black arrow) (H&E, x 200). c: (AIP + erdosteine treated group) showed less fiber disruption (red arrow) and myocytes degeneration (black arrow), but no necrosis (H&E, x 200). d: (AIP + NADPH treated group) showing preserved cardiac architecture in the form of parallel cylindrical branched muscle fibers (red arrow) and centrally placed nuclei (black arrow) (H&E, x 200).

Discussion:

In Egypt, aluminium phosphide is commonly used in grain storage as a fumigant pesticide (Elgazzar et al., 2022). Aluminium phosphide toxicity has a high mortality rate, almost reaching 100%. Most deaths occur within the first 12 hours due to cardiovascular toxicity, usually caused by dysrhythmia or contractile dysfunction (Beyranvand et al., 2019).

Phosphine gas is the highly toxic component of AIP, and its mechanism of toxicity is not clearly defined. It eventually leads to the induction of oxidative stress and apoptosis plus severe energy reduction in the cell (Sheta et al., 2019).

There is no specific antidote for AIP poisoning; so many substances have been proposed recently to achieve a better outcome for AIP cases (Yadav et al., 2021).

Erdosteine and exogenous NADPH have been shown to improve cardiac injuries (Zhu et al., 2019; Mutneja et al. 2020).

The present study showed a highly significant increase in the mean value of serum LDH level, a non-specific cardiac marker, in the AIP group when compared with the control group. This result was in agreement with Anand et al. (2012) and Anand et al. (2013), who reported the increase in LDH levels in the serum of rats and humans intoxicated with AIP, respectively.

This increase in LDH level can be explained by the ability of AIP to inhibit mitochondrial oxidative phosphorylation and shift cellular respiration into the anaerobic pathway (Jafari et al., 2015).

The current results showed that coadministration of erdosteine with AIP caused a highly significant decrease in the mean value of serum LDH levels when compared with the AIP group. This result was in agreement with Mutneja et al. (2020) and Yagmurca et al. (2003), who showed the protective effect of erdosteine on decreasing serum LDH levels after myocardial infarction and doxorubicin-induced cardiotoxicity, respectively. This result may be due to the antioxidant effect of erdosteine in decreasing oxidative stress-induced cardiac damage (Sener et al., 2007).

In the present study, the combined use of NADPH with AIP caused a highly significant decrease in the mean value of serum LDH when compared with the (AIP group) and (AIP + erdosteine group).

This result was similar to the study of Zhu et al. (2019), who reported that NADPH administration reduced circulating LDH levels in cardiac ischemic-

reperfusion injury in rats. This result may be due to the potent effect of NADPH on protecting the mitochondria and preserving energy production (Zhu et al., 2019).

Cardiac troponin I (cTnI) is released from cardiomyocytes into the bloodstream in case of myocardial damage, so it is a specific biomarker for cardiac injury. It is the gold standard for non-invasive diagnosis of myocardial injury in small animals, as it increases significantly at 4 hours after myocardial infarction and remains high for seven days (Hammadi et al., 2015).

According to the present results, the AIP treated group showed a highly significant increase in the mean value of the serum cTnI level when compared with the control group, indicating cardiac tissue damage. This result was in agreement with the studies of El Shehaby et al. (2021), Rahimi et al. (2018), and Sweilum et al. (2017) in rats. In human studies, Abdel Wahab et al. (2020) observed a highly significant increase in serum cTnI level, especially in patients with severe cardiovascular manifestations and ECG abnormalities, and recommended that cTnI can be a useful predictor of cardiac toxicity and mortality in patients with acute AIP phosphide poisoning.

The current results showed a highly significant decrease in cTnI level in the (erdosteine + AIP treated group) when compared with the AIP treated group. This result was in agreement with the study of Mutneja et al. (2020), who explained this result by the positive effect of erdosteine in maintaining the oxidant-antioxidant balance and attenuating inflammation and apoptosis in the myocardium.

The co-administration of NADPH with AIP in the current study caused a highly significant decrease in cTnI when compared with the AIP group but showed a non-significant difference with the control group and (AIP + erdosteine group). Zhu et al. (2019) coincided with this result and reported that NADPH can improve the cellular defense against oxidative stress by regeneration of the antioxidant enzymes, thus decreasing cardiomyocytes' injury.

Poisoning with AIP strongly induces apoptosis via cytochrome C release from mitochondria into the cytosol with subsequent activation of caspases. Cytochrome C release occurs due to altered mitochondrial membrane integrity caused by free radicals, with a subsequent reduction in the mitochondrial membrane potential and opening of the mitochondrial membrane transition pores (Hosseini et al., 2020).

The net result of flow cytometry analysis in the present study was that AIP markedly caused a highly significant decrease in the percent of live cardiomyocytes and markedly increased the percentage of late apoptotic and necrotic cardiomyocytes when compared with the control group. This result is supported by the flow cytometry findings of the following studies: Armandeh et al. (2021), Bameri et al. (2021), Samadi et al. (2021), Jafari et al. (2015), Solgi et al. (2015), and Abdolghaffari et al. (2015). This confirms that AIP can cause a marked inhibition to the electron transport chain with the induction of apoptosis, eventually causing cell death.

Also, erdosteine coadministration with AIP showed a highly significant slight increase in the percent of viable cardiomyocytes and a decrease in the total percent of apoptotic cardiomyocytes (early and late apoptotic) when compared with the AIP group. This result is in agreement with Mutneja et al. (2020), who showed the potential effect of erdosteine in decreasing cardiac apoptosis. This action may be due to the

antioxidant properties of erdosteine that can reduce the effect of oxidative stress on cardiac tissue. But, erdosteine use couldn't decrease the percent of necrotic cardiomyocytes in the current study.

Furthermore, exogenous NADPH co-administration with AIP in the current study was highly effective in increasing the cell viability, with a marked decrease in the total percent of apoptotic cardiomyocytes (early and late apoptotic) and a marked decrease in the percent of necrotic cardiomyocytes, when compared with the AIP group and (erdosteine & AIP group). This result is in the same line as Zhu et al. (2019), who showed the beneficial effects of NADPH in increasing the cell viability of the myocardium after ischemia-reperfusion injury.

It seems that NADPH can prevent AIP-induced apoptosis in cardiac tissue by reducing oxidative stress, improving mitochondrial function, reduction of cytochrome C release, and halting the processes of apoptosis and necrosis with cell shift into recovery before irreversible damage, thus alleviating AIP-induced cardiac toxicity.

The biochemical analysis of cardiac markers and flow cytometry of heart tissue was confirmed by the histopathological examination of the heart tissues collected in the present study, which revealed that AIP administration caused severe fiber disruption, disarranged cardiomyocytes with wide myocardium interstitium, areas of myocardial cell degeneration and necrosis, and congested blood vessels with perivascular inflammation. This result was in agreement with Bameri et al. (2021), El Shehaby et al. (2021), Abo El Wafa and El Noury (2020), Maleki et al. (2019), and Gouda et al. (2018), who found similar changes in heart histopathology in AIP-intoxicated rats.

In the current results, treatment with erdosteine showed less disruption of fibers and less cellular degeneration with no necrosis when compared with the AIP group. This result was similar to the studies of Mutneja et al. (2020), Selcoki et al. (2007), and Yagmurca et al. (2003), who found the same positive changes after the use of erdosteine in cardiac injury induced by isoproterenol, cyclosporine-A, and doxorubicin, respectively.

Moreover, the (NADPH + AIP treated group) showed a better alleviation of the AIP effect on heart tissue than that of the (AIP + erdosteine treated group), as it showed apparent normal cardiac architecture.

Conclusion:

Our results revealed that co-administration of erdosteine with AIP slightly improved serum cardiac markers and cardiomyocyte viability with a slight decrease in the percent of apoptosis. Co-administration of NADPH with AIP showed a marked improvement in serum cardiac markers, histopathological changes, a marked increase in myocardial cell viability, and a marked decrease in the percent of apoptotic myocytes. So, NADPH may be a promising treatment for AIP toxicity.

Recommendations:

Legalization of aluminium phosphide sale in Egypt is mandatory as it shouldn't be over the counter. The exact incidence of AIP poisoning in Egypt should be recorded in all governorates. Further studies are needed to investigate the survival time in rats intoxicated with AIP after administration of exogenous NADPH and to investigate the positive effect of exogenous NADPH in the treatment of AIP in humans.

Conflict of interest: The authors declare that there is no conflict of interest.

Funding status: There is no financial support.

Acknowledgment: The authors are grateful to the technical and cooperative staff at the departments of Pathology, Faculty of Medicine, Central Lab of Veterinary Medicine, Benha University, and Molecular Immunology, Mansoura University, Egypt for their support during the study.

References:

Abdel Wahab, M., Shalaby, S., El Awady, E., et al. (2020). ‘Assessment of the role of total antioxidant capacity and troponin I as possible predictors for phosphides-induced cardiotoxicity’, *Ain Shams J. Forensic Med. Clin. Toxic.*, 34(1), pp. 82-94.

Abdolghaffari A.H., Baghaei A., Solgi R., et al. (2015). ‘Molecular and biochemical evidences on the protective effects of triiodothyronine against phosphine-induced cardiac and mitochondrial toxicity’, *Life Sci.*, 139, p. 30–39.

Abo El Wafa, S.M., and El Noury, H.A. (2020). ‘Can rutin ameliorate aluminum phosphide-induced acute cardiac toxicity in adult albino rats?’ *Int. J. Pharmacol. Toxicol.*, 8(1), p. 8-14.

Agledal, L., Niere, M., and Ziegler, M. (2010). ‘The phosphate makes a difference: cellular functions of NADP’, *Redox Rep.*, 15(1), p. 2– 10.

Ahmadi, J., Joukar, S., Anani, H., et al. (2018). ‘Dihydroxyacetone as a definitive treatment for aluminium phosphide poisoning in rats’, *Arh Hig Rada Toksikol.*, 69 (2), p.169-177.

Aminjan, H.H.; Abtahi, S.R.; Hazrati, E.; et al. (2019). ‘Targeting of oxidative stress and inflammation through ROS/NF-kappa B pathway in phosphine-induced hepatotoxicity mitigation’, *Life Sci.*; 232, 116607.

Anand, R., Kumari, P., Kaushal, A., et al. (2012). ‘Effect of acute aluminum phosphide exposure on rats: a biochemical and histological correlation’, *Toxicol. Lett.*, 215(1), p. 62–69.

Anand, R., Sharma, D.R., Verma, D., et al. (2013). ‘Mitochondrial electron transport chain complexes, catalase and markers of oxidative stress in platelets of patients with severe aluminum phosphide poisoning’, *Hum. Exp. Toxicol.*, 32(8), p. 807–816.

Armandeh, M., Bameri, B., Baeeri, M., et al. (2021). ‘The role of levosimendan in phosphine-induced cardiotoxicity: evaluation of electrocardiographic, echocardiographic, and biochemical parameters’, *Toxicol. Mech. Methods*, 31(9), p. 631–643.

-
- Badawi, S.M., Alseidy, A.M., Alfeki, A.K., et al. (2018).** ‘Metal phosphide poisoning in Menoufia University Hospitals’, *Menoufia Med. J.*, 31(3), p. 816-821.
- Bameri, B., Armandeh, M., Baeri, M., et al. (2021).** ‘Electrocardiographic, hemodynamic, and biochemical evidence on the protective effects of exenatide against phosphine-induced cardiotoxicity in rat model’, *Hum. Exp. Toxicol.*, 40(12), p. S381–S396.
- Beyranvand, M.R., Farrokhi, S., Peyvandi, H.; et al. (2019).** ‘The effects of amiodarone prophylaxis on cardiac dysrhythmia in acute aluminium phosphide poisoning’, *Arh. Hig. Rada. Toksikol.*, 70(1), pp. 49–53.
- Birdane, Y.O., Avci, G., Birdane, F.M., et al. (2021).** ‘The protective effects of erdosteine on subacute diazinon-induced oxidative stress and inflammation in rats’, *Environ. Sci. Pollut. Res. Int.*, 29(15), pp. 21537–21546.
- Demiralay, R., Gürsan, N., and Erdem, H. (2006).** ‘Regulation of sepsis-induced apoptosis of pulmonary cells by posttreatment of erdosteine and N-acetylcysteine’, *Toxicology*, 228(2-3), pp. 151– 161.
- El Naggar, A.R.M. and El Mahdy, N.M. (2011).** ‘Zinc phosphide toxicity with a trial of tranexamic acid in its management’, *J. Adv. Res.*; 2(2), p. 149–156.
- El Shehaby, D.M., Sayed, S.A., Abd El-Kareem, D.M., et al. (2021).** ‘Trimetazidine with hyperinsulinemia-euglycemia, N-acetyl cysteine, and vitamin C: A new approach concept for management of aluminum phosphide poisoning’, *J. Biochem. Mol. Toxicol.*, 36(1), e22931.
- Elgazzar, F.M., Shama, M.A., Shoeib, O., et al. (2022).** ‘The role of echocardiographic findings in estimating survival probability of intensive care unit admitted aluminum phosphide poisoned patients’, *J. Med. Toxicol.*, 18(2), pp. 128–138.
- Eshraghi, A., Rajaei, N., Mood, M.B., et al. (2019).** ‘Changes of QT dispersion in patients suffering from aluminum phosphide poisoning (Rice Pill)’, *Open Access Maced. J. Med. Sci.*, 7(14), pp. 2251-2255.
- Farhana, A. and Lappin, S. L. (2021).** ‘Biochemistry, lactate dehydrogenase’, *In StatPearls [Internet]. Treasure Island (FL): StatPearls Publishing.* Available from: <https://www.ncbi.nlm.nih.gov/books/NBK557536>.
- Farzaneh, E., Ghobadi, H., Akbarifard, M., et al. (2018).** ‘Prognostic factors in acute aluminium phosphide poisoning: A risk prediction nomogram approach’, *Basic Clin. Pharmacol. Toxicol.*, 123(3), pp. 347–355.
- Ghazi, M.A. (2013).** “Wheat pill (aluminum phosphide) poisoning”; commonly ignored dilemma. A comprehensive clinical review’, *Professional Med. J.*, 20(6), pp. 855-863.
- Gouda, A.S., El-Nabarawy, N.A., and Ibrahim, S.F. (2018).** ‘Moringa oleifera extract (Lam) attenuates Aluminium phosphide induced acute cardiac toxicity in rats’, *Toxicol. Rep.*, 5, pp. 209 - 212.
-

-
- Hammadi, M.H., labiy, N.M., and Hamoodi, S.R. (2015).** ‘Study the predictive value of Troponin –I and histopathological changes during acute and chronic myocardial infarction in adult male rats’, *M.J.S.*, 26(2), pp. 13-17.
- Hosseini, S.F., Forouzes, M., Maleknia, M., et al. (2020).** ‘The molecular mechanism of aluminum phosphide poisoning in cardiovascular disease: pathophysiology and diagnostic approach’, *Cardiovasc. Toxicol.*, 20(5), pp. 454–461.
- Jafari, A., Baghaei, A., Solgi, R., et al. (2015).** ‘An electrocardiographic, molecular and biochemical approach to explore the cardioprotective effect of vasopressin and milrinone against phosphide toxicity in rats’, *Food Chem. Toxicol.*, 80, pp. 182–192.
- Lewis, C.A., Parker, S.J., Fiske, B.P., et al. (2014).** ‘Tracing compartmentalized NADPH metabolism in the cytosol and mitochondria of mammalian cells’, *Mol. Cell*, 55(2), pp. 253–263.
- Lyubimov, A.V. and Garry, V.F. (2010).** ‘Phosphine’. In: Hayes' Handbook of Pesticide Toxicology, 3rd ed., Krieger R. (ed.), Elsevier/Academic Press, London, UK, p. 2259-2266.
- Maleki, A., Hosseini, M.J., Rahimi, N., et al. (2019).** ‘Adjuvant potential of selegiline in treating acute toxicity of aluminium phosphide in rats’, *Basic Clin. Pharmacol. Toxicol.*, 125(1), pp. 62–74.
- Mutneja, E., Verma, V.K., Malik, S., et al. (2020).** ‘Erdosteine salvages cardiac necrosis: Novel effect through modulation of MAPK and Nrf-2/HO-1 pathway’, *J. Biochem. Mol. Toxicol.*, 34(12), e22590.
- Rahimi, N., Abdolghaffari, A. H., Partoazar, A., et al. (2018).** ‘Fresh red blood cells transfusion protects against aluminum phosphide induced metabolic acidosis and mortality in rats’, *PLoS ONE*, 13(3), e0193991.
- Salah Eldin, H. and Azim, S. (2018).** ‘Pattern of deliberate self-poisoning cases admitted to Poison Control Center Ain Shams University Hospitals during the years 2015-2016’, *Ain Shams J. Forensic Med. Clin. Toxicol.*, 30(1), pp. 9-17.
- Samadi, M., Baeri, M., Haghi-Aminjan, H., et al. (2021).** ‘On the mechanisms of taurine in alleviating electrocardiographic, hemodynamic, and biochemical parameters following aluminum phosphide cardiotoxicity’, *Food Chem. Toxicol.*, 154, 112347.
- Sciuto, A.M., Wong, B.J., Martens, M.E., et al. (2016).** ‘Phosphine toxicity: a story of disrupted mitochondrial metabolism’, *Ann. N. Y. Acad. Sci.*, 1374(1), pp. 41–51.
- Selcoki, Y., Uz, E., Bayrak, R., et al. (2007).** ‘The protective effect of erdosteine against cyclosporine A-induced cardiotoxicity in rats’, *Toxicology*, 239(1-2), pp. 53–59.

-
- Sener, G., Aksoy, H., Sehirli, Ö., et al. (2007).** ‘Erdosteine Prevents Colonic Inflammation Through Its Antioxidant and Free Radical Scavenging Activities’, *Dig. Dis. Sci.*, 52(9), pp. 2122–2132.
- Sheta, A.A., El-Banna, A.S., Elmeguid, R.A.; et al. (2019).** ‘A study of the predictive factors of mortality in acute poisoning with aluminum phosphide with special reference to echocardiography and SOFA score’, *Environ. Sci. Pollut. Res. Int.*, 26(32), pp. 33135– 33145.
- Solgi, R., Baghaei, A., Golaghaei, A., et al. (2015).** ‘Electrophysiological and molecular mechanisms of protection by iron sucrose against phosphine-induced cardiotoxicity: a time course study’, *Toxicol. Mech. Methods*, 25(4), pp. 249–257.
- Sweilum, O.A.H., Kandeel, F.S., and Noya, D.A.R. (2017).** ‘Management of acute aluminum phosphide toxicity in rat model with a novel intervention, a trial of boric acid’, *Egypt J. Forensic Sci. Appl. Toxicol.*, 17(2), pp. 57-72.
- Tribukait, B., Moberger, G. and Zetterberg, A. (1975).** ‘Methodological aspects of rapid-flow cytofluorometry for DNA analysis of human urinary bladder cells’, In: Haenen C, Hillen H., Wessels S., (eds.) *Pulse Cytophotometry*, part 1. European Press Medicion, Ghent; pp. 55-60.
- Vermes, I., Haanen, C., Steffens-Nakken, H., et al. (1995).** ‘A novel assay for apoptosis. Flow cytometric detection of phosphatidylserine expression on early apoptotic cells using fluorescein labelled Annexin V’, *J. Immunol. Methods*, 184(1), pp. 39–51.
- Xiao, W., Wang, R.S., Handy, D.E., et al. (2018).** ‘NAD(H) and NADP(H) redox couples and cellular energy metabolism’, *Antioxid. Redox Signal*, 28(3), pp. 251–272.
- Yadav, D., Bhattacharyya, R., and Banerjee, D. (2021).** ‘Acute aluminum phosphide poisoning: The menace of phosphine exposure’, *Clin. Chim. Acta*, 520, pp. 34–42.
- Yagmurca, M., Fadillioglu, E., Erdogan, H., et al. (2003).** ‘Erdosteine prevents doxorubicin-induced cardiotoxicity in rats’, *Pharmacol. Res.*, 48(4), pp. 377–382.
- Zhu, J., Wang, Y.F., Chai, X.M., et al. (2019).** ‘Exogenous NADPH ameliorates myocardial ischemia-reperfusion injury in rats through activating AMPK/mTOR pathway’, *Acta Pharmacol. Sin.*, 41(4), pp. 535–545.

التأثيرات المحسنة لعقارى الإردوشتاين ونيكوتيناميد أدينين ثنائي نوكليو تيد الفوسفات المختزل علي سمية القلب الناتجة عن فوسفيد الألومنيوم فى الجرذان البيضاء البالغة

وفاء سامي علي البدوي¹، إسلام سامى محمد متولي¹، نجاح السيد محمد علي¹، مها محمد مختار¹

قسم الطب الشرعي و السموم الإكلينيكية¹

كلية الطب البشري – جامعة بنها

الهدف من الدراسة الحالية هو إستكشاف التأثيرات المحسنة لعقار الإردوشتاين ومادة نيكوتيناميد أدينين ثنائي نوكليو تيد الفوسفات المختزل علي سمية القلب الناتجة عن التسمم بفوسفيد الألومنيوم فى الجرذان البيضاء البالغة وذلك من خلاص فحص مستوي (التروبونين القلبي وإنزيم اللاكتات ديهيدروجينيز) فى الدم وفحص مدي حيوية وموت خلايا عضلة القلب من خلال جهاز الفلوسيتوميترى. تم إجراء هذه التجربة علي أربعة وخمسون جرذاً، حيث تم تقسيمهم إلي سبع مجموعات كالتالى: المجموعة الضابطة السلبية، مجموعة المواد المذيبة، المجموعة الضابطة الإيجابية للإردوشتاين، المجموعة الضابطة الإيجابية لنيكوتيناميد أدينين ثنائي نوكليو تيد الفوسفات المختزل ، مجموعة فوسفيد الألومنيوم (12 مجم / كجم بالفم مرة واحدة)، مجموعة فوسفيد الألومنيوم 12 مجم /كجم ثم يتبع بعد ساعة بالإردوشتاين 150 مجم / كجم بالفم مرة واحدة، مجموعة فوسفيد الألومنيوم 12 مجم /كجم بالفم مرة واحدة ثم يتبع بعد ساعة ب(نيكوتيناميد أدينين ثنائي نوكليو تيد الفوسفات المختزل 16 مجم / كجم عن طريق الحقن الوريدي مرة واحدة. بعد مرور ثمان ساعات من بداية التجربة تم أخذ عينات الدم من الضفيرة الدموية الخلفية للعين من أجل فحص إنزيمات القلب فى الدم وكذلك تم فتح تجويفي الصدر والبطن لإخراج القلب من أجل إجراء تحليل الفلوسيتوميترى و الهستوباثولوجى. أوضحت النتائج أن التسمم بفوسفيد الألومنيوم سبب زيادة فى إنزيمات القلب فى الدم وإنخفاض فى معدل حيوية خلايا عضلة القلب وزيادة نسبة الموت الخلوي فيها. إعطاء عقار الإردوشتاين مع فوسفيد الإلومنيوم ساعد فى خفض ارتفاع إنزيمات القلب نسبياً مع تحسن طفيف فى معدل حيوية خلايا عضلة القلب و نقص فى معدل موت الخلايا. أما إعطاء مادة نيكوتيناميد أدينين ثنائي نوكليو تيد الفوسفات المختزل مع فوسفيد الألومنيوم أحدث تحسن ملحوظاً فى خفض مستوي إنزيمات القلب فى الدم مع تحسن ملحوظ فى نسبة حيوية خلايا عضلة القلب وإنخفاض ملحوظ فى معدل موت الخلايا ، وقد تم تأكيد هذه النتائج بالفحص الهستوباثولوجى لأنسجة القلب المأخوذة من كل مجموعة. لذلك أثبتت الدراسة الحالية أن مادة نيكوتيناميد أدينين ثنائي نوكليو تيد الفوسفات المختزل بالحقن الوريدي من الممكن أن يكون علاجاً واعداً لحالات التسمم بفوسفيد الألومنيوم.